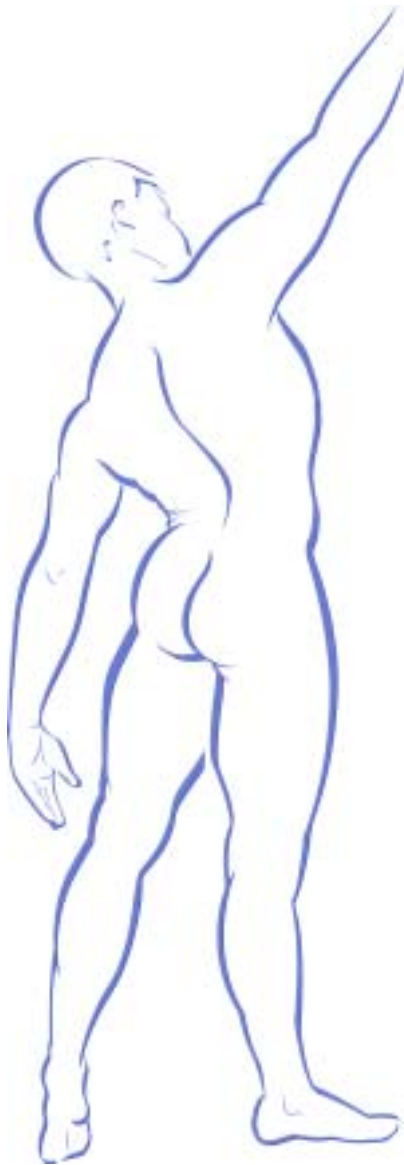


Robotic Radical Prostatectomy

*Kevin M. Slawin
& Naveen Kella*



Over the past 5 years, the areas of debate regarding the treatment of localized prostate cancer have shifted dramatically. Prior to this period, there were many strong advocates resisting PSA-based screening for prostate cancer and questioning the role of treatment for localized disease in the absence of randomized trials proving a survival benefit. However, with the striking declines in advanced disease associated with screening programs, most dramatically in Tyrol, Austria, together with the unequivocal randomized data from Sweden proving a survival benefit from radical prostatectomy for clinically localized prostate cancer, the value of surgery for these patients is less frequently challenged. Key efforts now are focused on determining the appropriate PSA cutpoints for prostate cancer screening and on addressing the problem of overtreatment of patients with disease of lower grade and volume.

Variables often discussed now are the efficacy and morbidity of various treatment options for clinically localized prostate cancer. Treatment decisions require that patients and physicians weigh the risks and benefits of each option. Newer, minimally invasive options for the treatment of prostate cancer, such as robotic prostatectomy, impact this equation by offering high cancer control rates similar to those achieved with open, radical prostatectomy, but with a lower short-term, and potentially long-term, morbidity. The first great strides in addressing the morbidity of prostate cancer surgery were made through a better understanding of the surgical anatomy of the prostate, urinary sphincter, and neurovascular bundles, along with increased experience, as the number of radical prostatectomies performed ballooned in the late 1980s and 1990s [1]. These efforts led to a steady improvement in cancer control along with an improved quality of life for patients in the areas of urinary and sexual functions after surgery for prostate cancer.

More recently, technical advances in instrumentation, primarily in support of a laparoscopic approach to surgery, have supported a second revolution in radical prostatectomy surgery. Whereas laparoscopic approaches to the kidney gained acceptance by urologists, laparoscopic prostatectomy initially remained less popular because of the high degree of technical difficulty of this complex operation, and the long and steep “learning curve” associated with achieving its mastery. Challenges with laparoscopic prostate surgery include lack of depth perception, anti-intuitive “reverse motion” of the instruments, amplification of hand tremor, diminished dexterity in fine movements with the use of laparoscopic instruments due to the limited “degrees of freedom” (4 versus 6 for a surgeon’s

own hands), awkward ergonomics for the operating physician and a reduction in tactile feedback. Despite these challenges, a small cadre of talented surgeons, many of whom were expert laparoscopic surgeons but with limited training in oncology, became adept at laparoscopic prostatectomy, surging to the forefront of the field of surgical management of prostate cancer.

However, through the relentless drive of technology in the fields of computers and microelectronics, robotic techniques have emerged to provide a viable pathway for classically trained oncologic surgeons, skilled in open radical prostatectomy after years of practice and experience, to translate these skills into a minimally invasive approach to radical prostatectomy. This has leveled the field for all surgeons interested in pursuing minimally invasive approaches to prostate cancer surgery. The DaVinci robotic system (Intuitive Surgical, Inc., Mountain View, CA) allows surgeons to sit comfortably at a console and immerse themselves in a magnified (up to ten-fold) and 3-dimensional view of the surgical field. At the console, the surgeon controls instruments located on the surgical cart, which is the apparatus located patient-side. The surgeon has control of the stereoscopic camera as well as up to three robotic arms, which can wield various and interchangeable instruments. The instruments are able to articulate with wrist-like movements that allow six degrees of motion compared with four degrees possible with

conventional laparoscopic instruments. Computer-filtration can eliminate surgeon tremor and finely scale a surgeon's motions up to 5:1, if desired. Moreover, instrument motions occur without perceptible delay to the surgeon. Because tactile feedback is limited, the surgeon is forced to rely on visual cues while dissecting and handling tissue.

The first robotic radical prostatectomies were performed by Binder and Kramer in Germany in May 2000 [2]. The advantages provided by robotic assistance for this highly complex and demanding surgical procedure have resulted in an increase in the number of surgeons performing the procedure. In 2004, robotic assistance was used in nearly 10% of all radical prostatectomies performed in the United States.. However, the learning curve is still significant for performing a robotic-assisted laparoscopic prostatectomy. A study by Ahlering et al showed that 20 robotic cases were needed to achieve four-hour proficiency by a surgeon experienced in open procedures. For the initial 45 patients, the mean operating time was 3.45 hours (range 2.5–5.1 hours) [3]. Another requirement in laparoscopic surgery is a skilled assistant. Whereas many DaVinci robotic systems have an additional instrument arm, which allows the surgeon himself to help provide retraction, an experienced assistant is still invaluable for providing suction, irrigation, additional retraction, rapid instrument changes and occasional surgical cart troubleshooting.

GENERAL BENEFITS OF ROBOTIC SURGERY

Clear benefits of robotic surgery are the reduction in postoperative pain and length of hospitalization because of the minimally invasive nature of the procedure. Generally, our experience is that 90% of patients are ready for discharge the day after surgery. Reports in the literature corroborate our finding. Tewari et al. noted that 93% of their patients are ready for discharge within 24 hours of surgery [8]. Decreased blood loss associated with laparoscopic and robotic-assisted surgery is well documented in the literature. Blood loss in reported series has consistently been less than 200 cc and transfusion rates have been negligible. Narcotic usage is minimal, and many patients may not need

patient-controlled analgesia with morphine. Many centers, including ours, find that a 24 hour course of ketorolac is sufficient for pain control during hospitalization followed by Tylenol and hydrocodone tablets afterwards. The Foley catheter remains in situ for one week. Earlier removal is possible but raises the risk of urinary retention.

Return to work or return to baseline activities seems anecdotally to occur earlier with robotic-operated patients. We allow patients to return to work and regular activities in as early as one to two weeks after surgery, especially those men who are not physical laborers.

URINARY CONTINENCE AND ROBOTIC SURGERY

Reports indicate that urinary continence returns earlier with a robotic prostatectomy. Tewari et al. observed that 50% of patients achieved continence within 44 days after robotic surgery compared to 160 days with open surgery [8]. In our experience, it is not unusual for patients to report wearing zero to one pad shortly after removal of the Foley catheter at one week, but we have not yet fully analyzed and reported our continence rates with validated questionnaires.

Further evaluation of continence rates is even more interesting when examining the rates of continence achieved by highly experienced open surgeons. For example, Ahlering et al. compared a sequential series of 60 robotics patients (starting after his 45th robotic case) with the last 60 patients (out of hundreds) who had open surgery. From the robotics group, 76% of patients were completely continent 3 months after surgery, a proportion similar to that for his last group of 60 patients who underwent open radical prostatectomy [9].

With the robotic approach, excellent visualization at the prostatic apex results in maximal preservation of urethral length

and minimizes inadvertent cautery damage to surrounding musculature and nerves. Whereas definite data are lacking, many consider preservation of urethral length as a contributor to return of continence [10]. Another aspect of the robotic approach is the ability to construct a watertight anastomosis. Again, whether urinary extravasation truly contributes to incontinence is an unanswered question. However, the ability to prevent urinary leaks does allow earlier removal of the catheter and perhaps reduces the incidence of bladder neck contracture due to urinary extravasation. Indeed, the reported incidence of bladder neck contracture in the robotic literature is extremely low.

In summary, promising data suggest an advantage in speed of return of continence and possibly total rate of return of continence with robotics. Additionally, as in open surgery, a surgeon's technique may ultimately be the driving factor in urinary continence. Robotics may better allow preservation of urethral length, construction of a watertight anastomosis, and bladder neck sparing, but surgeon skill and experience are still vital for consistent outcomes for urinary continence.

SEXUAL POTENCY AFTER ROBOTIC SURGERY

In laparoscopy, dissection of the prostate proceeds primarily in an antegrade fashion. The posterolateral neurovascular bundles are generally thickest proximally at the base of the prostate. As they are dissected under direct vision, they can be swept away towards the apex of the gland. Once at the apex, vision with robotics is superior to that with open surgery as long as the field is relatively bloodless. This visualization allows precise dissection of the neurovascular bundle away from the prostate at its apex. In total, these efforts likely contribute to preservation of sexual function. Of course, principles of nerve preservation during open surgery also apply to robotic surgery. Along with knowledge of the anatomy of

the neurovascular bundles, minimal use of cautery and gentle handling of the neurovascular bundles are important.

Long-term data are available from some institutions that adopted robotics relatively early. For example, Tewari et al. indicated that robotic surgery patients had an earlier return of erections than patients who had open surgery (50% return at a mean of 180 days versus 440 days for open radical prostatectomy patients). Undoubtedly, as with urinary continence, surgical technique and surgeon experience, rather than the use of the robot, will still be the primary factor determining the eventual success of nerve-sparing surgery.

COSTS OF ROBOTIC SURGERY

On a simplistic level, assessing the robotic prostatectomy from a cost-profit standpoint generally shows a poor financial return for the hospital. For example, in one report, a single center in the United States performed 174 procedures over a period of 18 months. The total hospital cost per radical prostatectomy was greater than the reimbursement per case by \$148. In addition, this figure does not even account for the initial investment and annual maintenance for the robot, typically over 1 million dollars and 100,000 dollars, respectively [11].

At The Methodist Hospital in Houston, Texas, robotic prostatec-

tomy produces net revenue, although over the past three years, open radical prostatectomy generated approximately \$1000 more per case for the hospital. With growing experience and the currently decreasing time in the operating room achieved more recently, this differential in revenue will narrow. Further studies may also need to look beyond the hospital's finances and examine the cost of a radical prostatectomy from society's standpoint. Factors such as an earlier return to work, an earlier return of continence, and improved sexual function should be investigated to determine whether they are sufficient to justify the overall higher cost of robotic prostatectomy.

PREOPERATIVE CONSIDERATIONS

In general, radical prostatectomy is a treatment option for men with a life expectancy of 10 years or more. Any patient who is a candidate for open extirpation may also be a candidate for a laparoscopic robotic procedure. Conditions making laparoscopy more challenging include previous prostate surgery, whether open or endoscopic; abdominal surgeries, especially with usage of mesh; and adjuvant or salvage treatment, whether after radiation, hormonal therapy, or cryotherapy. The presence of a known median lobe calls for a surgeon who has achieved a higher level of expertise and comfort with this operation. Less experienced surgeons would be more likely to leave a portion of the median lobe behind, or have more difficulty in reconstructing the potentially wide bladder neck. Repair can be done posteriorly or anteriorly on the bladder neck depending on surgeon preference. The technique for performing the bladder neck reconstruction roboti-

cally is similar to the technique used in open surgery, but it can be difficult for the inexperienced robotic surgeon. Furthermore, a large prostate tends to lead to longer operating time because of the difficulty inherent in manipulating and placing traction on the prostate in a reduced space. However, we have successfully removed prostates over 130 grams in size. Removal of pelvic lymph nodes is recommended for patients with higher PSA or Gleason Score. Surgeons can perform pelvic lymph node dissection laparoscopically with the DaVinci system, although a more complete node dissection can be achieved through the more standard, open procedure. The pneumoretroperitoneum can flatten the iliac veins, and dissection must be done delicately to avoid injury. Although a transperitoneal approach reduces the risk of a lymphocele, we exclusively utilize a retroperitoneal approach for robotic prostatectomy.

PREOPERATIVE PREPARATION

Surgeons need to discuss with their patients the risks of laparoscopy and traditional open surgery as well as the possibility of a robotic malfunction, which have been noted but are rare. Bowel preparations can be administered according to surgeon preference, although a simple enema on the morning of surgery is

the only preparation we recommend for both robotic and open prostatectomy. Especially during the transition period for “newly minted” robotic surgeons, patients should be keenly made aware that the surgeon may convert the case to an open approach if he for any reason, he feels the patient’s interests favor conversion.

Positive Margin Rates of Multiple Published Series

Series		Positive margins, %
Soloway (review of several centers)	(Open)	28
Lepor	(Open)	26
Scardino	(Open, 1154 cases) (498 cases)	pT2 7.8 pT3 20.8
Walsh	(Open, 4683 cases from 1997–2001)	All 9.2 pT3 22.7
Guillonnet	(Laparoscopic, 400 cases at MSKCC)	pT2 6.4 pT3 20.5
Abbou	(Laparoscopic)	20
Rassweiler	(Laparoscopic)	24
Turk	(Laparoscopic)	26
Bollens	(Laparoscopic)	22
Sulser	(Laparoscopic)	18
Menon	(Robotic, >100 cases)	26, 17, 6
Ahlering	(Robotic, 140 cases)	24
Patel V	(Robotic, 450 cases)	10.5

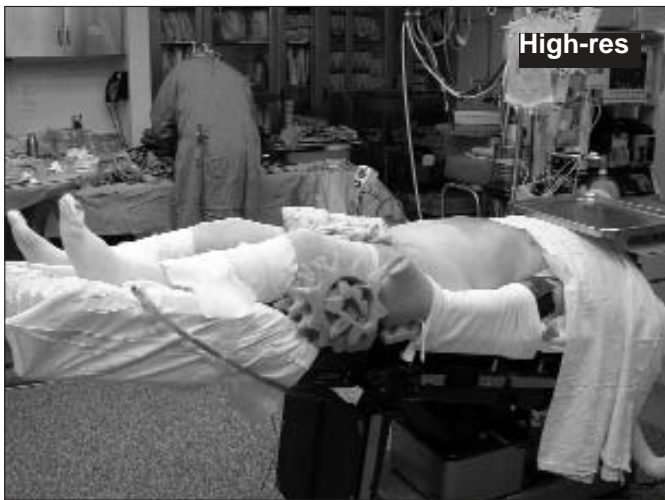► **FIGURE 13-1.** Positive margin rates of multiple published series. In oncology, a positive margin means an incomplete excision of the tumor. Whereas half or more of prostate cancer patients with a positive margin will remain cancer-free with long-term follow-up, efforts to reduce positive margins clearly lead to better biochemical progression-free rates [4]. In a study by Epstein *et al*, patients with positive margins had 10-year biochemical progression-free rates of 55%, whereas patients with negative margins had progression-free rates of 80% [5]. With open surgery, it has been shown that surgical technique is an independent predictor of positive margin status [6]. In robotics, the surgeon’s technique also influences surgical margin rates. The improvement in visualization and precise movements during a robotic procedure come at the expense of tactile sensation, which some surgeons rely on to detect the presence of tumor extension [7]. Early series in robotics appear to show positive margin rates, which are at least comparable with many open and laparoscopic surgical series.

Baylor College of Medicine Single Surgeon Positive Margin Rate with Robotic Prostatectomy (n=117 cases) (Unpublished)

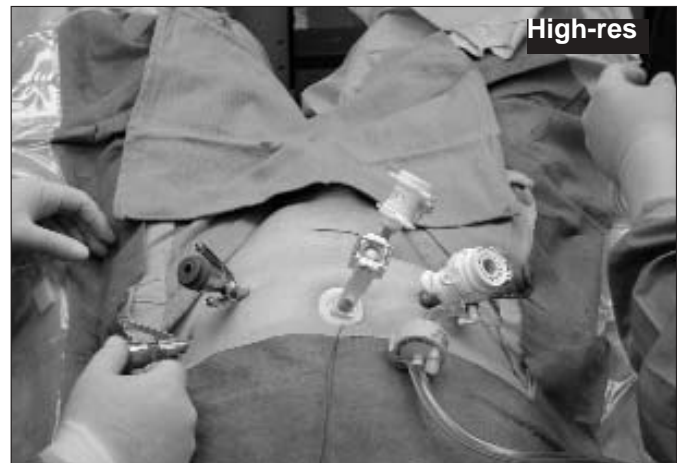	<i>First 50 cases</i>	<i>Second 50 cases</i>	<i>Last 17 cases</i>
pT2	42 (50)=84%	32 (50)=64%	16 (17)=94%
% + SM	3 (42)=7%	1 (32)=3%	0 (16)=0%
pT3	8 (50)=16%	13 (50)=26%	1 (17)=5.9%
% + SM	2 (8)=25%	3 (13)=23%	0 (1)=0%

► **FIGURE 13-2.** Baylor College of Medicine single surgeon positive margin rate with robotic prostatectomy. Positive margins typically are encountered at the prostatic apex or along the posterolateral aspect of the prostate where the neurovascular bundles are located. Interestingly, these are both locations where the robotic or laparoscopic approach can provide excellent visualization. With a straight (0 degree) or angled down (30 degree down) lens, surgical detail generally unappreciated in open surgery can be visualized to allow a more anatomical dissection, especially at the apex and alongside the neurovascular bundles. As

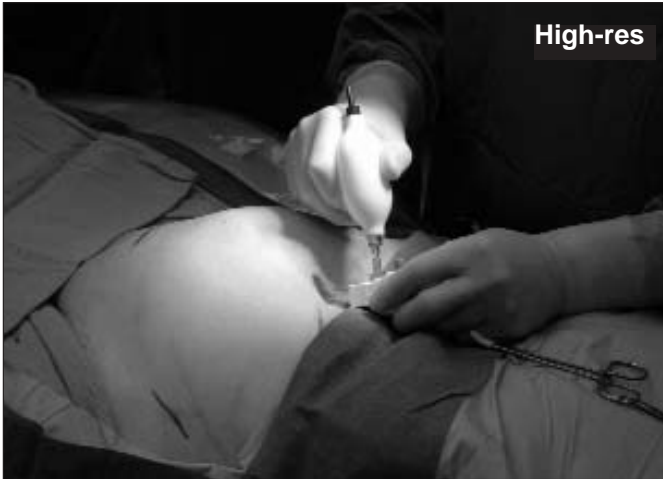
surgeons experienced with radical prostatectomy migrate to the robotic platform, positive margin rates should improve. At Baylor College of Medicine, the single surgeon positive margin rate shows continuing improvement with experience, as shown in this table, and is comparable to those reported for open radical prostatectomy at our center, as well as at other centers of excellence, as shown in Table 1. More importantly, data regarding long-term PSA PFS with robotic prostatectomy will require maturation of data to compare this more clinically significant outcome measure.



► **FIGURE 13-3.** Patient positioning. The patient is positioned supine in lithotomy position, or with split legs, to allow access for the robot between the legs of the patient. Arms are padded and tucked to the sides. This allows space for the assistant to work freely and also avoids possible interference with the optional fourth arm of the DaVinci robot. Depending on whether the approach is transperitoneal or extraperitoneal, the patient is placed maximally to moderately in Trendelenburg position. The surgical prep covers the genitalia to the xiphoid process and stretches laterally to just beyond the anterior superior iliac spines. For a four-arm system, the fourth arm is typically routed below the patient's left leg, or in some institutions, the right leg. The master-slave system of the DaVinci surgical system is comprised of the following: a surgeon's console with a 3-dimensional viewer, the surgical robot with either two or three working arms, and a camera arm. A patient-side assistant attaches instruments to the robotic arms and can change them throughout the course of the procedure. The assistant typically controls one or two laparoscopic ports for suctioning, retraction, suture passing, and eventual entrapment of the prostate in a specimen bag. At the console, the surgeon continually uses his hands and feet to move the instruments, to activate monopolar or bipolar electrocautery, and to position the camera.

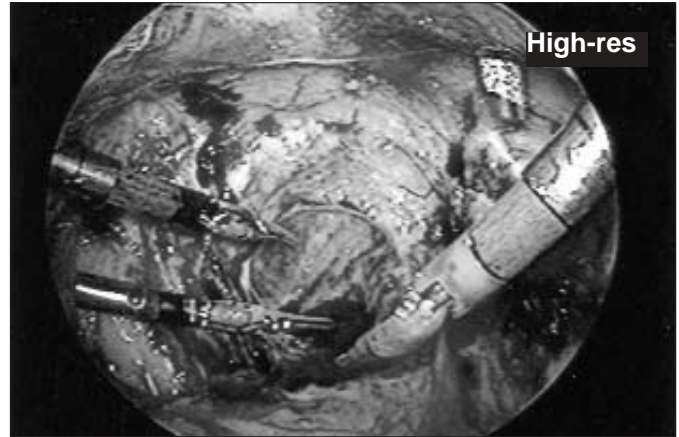


► **FIGURE 13-4.** Port placement. Two factors, the route of the procedure and the anatomy of the pubic bone, pubic rami, and anterior superior iliac spines primarily determine port placement. The decision to perform surgery transperitoneally or extraperitoneally dictates placement of the camera port 1 or 2 cm above the umbilicus if transperitoneal, or just below the umbilicus if extraperitoneal. The remaining ports are placed in a semicircular fashion, but the pubis should be used as the frame of reference, rather than the camera port [12]. The robotic arms have a finite length and positioning them further than 18 cm away from the pubis (measured when insufflated) risks making them unavailable for performance of the apical dissection or for the anastomosis. At the same time, the DaVinci arms need to be positioned sufficiently distant from the pubis to allow the anterior bladder takedown or a pelvic lymph node dissection. The robotic arms also need to be placed far enough apart to prevent instrument interaction. An 8 to 10 cm distance between each port (insufflated) appears ideal for avoiding interaction. In order to properly position the ports, we initially map out on the patient's skin the superior border of the pubic bone and the anterior superior iliac spines. After placement of the camera port, the primary right and left robotic arm positions are measured and marked on the lower abdomen. The position of the "fourth" arm is marked on the abdomen laterally to the left of the primary robotic trocar on the left side, all the way to the anterior iliac spine. Finally, a 5 mm assistant port is marked, two-finger breadths above the pubic bone, just to the right of the midline, and a 12 mm port between the camera port and the right sided robotic trocar are positioned. The 12 mm port is needed for passing needles, suctioning, and potentially for stapling the dorsal vein, as well as for entrapping the specimen.




High-res

► **FIGURE 13-5.** Retroperitoneal insufflation. After making a 1–2 cm incision just below the umbilicus, the linea alba is exposed with an Army-Navy retractor, and the anterior rectus sheath is incised with an 11 blade, taking care to leave intact the posterior rectus fascia. Using finger dissection, the Space of Rhetzius is developed. A 2-0 prolene suture is placed at the upper apex of the fascial incision and tagged. A “kidney-shaped” balloon dissector is then placed into the developed space and manually insufflated. After removing the deflated balloon dissector, the 10–12 mm camera port is inserted and a pneumoretroperitoneum of 13 mm Hg is established.



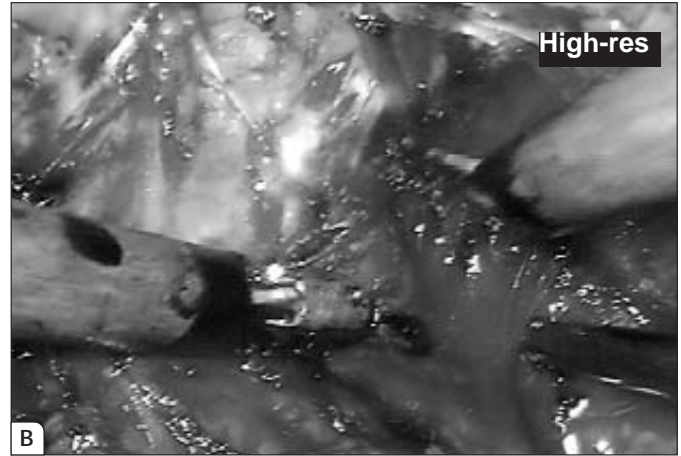
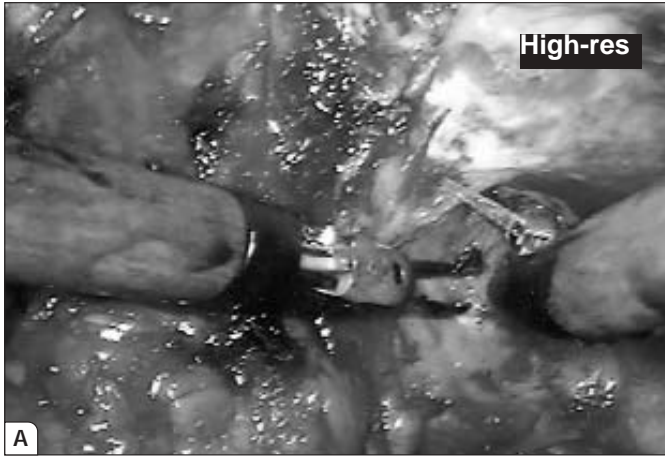High-res

► **FIGURE 13-6.** Wide angle start. After approximately our first 50 cases, we have switched exclusively to the extraperitoneal approach, which we prefer because it requires less Trendelenburg, avoids the physiologic consequences of a pneumoperitoneum, takes advantage of the peritoneum to retract and protect the small bowel, and is less problematic in the rare event of a urine leak postoperatively. Using an extraperitoneal approach, the bladder is swept posteriorly by the pneumoretroperitoneum and the surgeon has immediate access to the prostate at the outset.



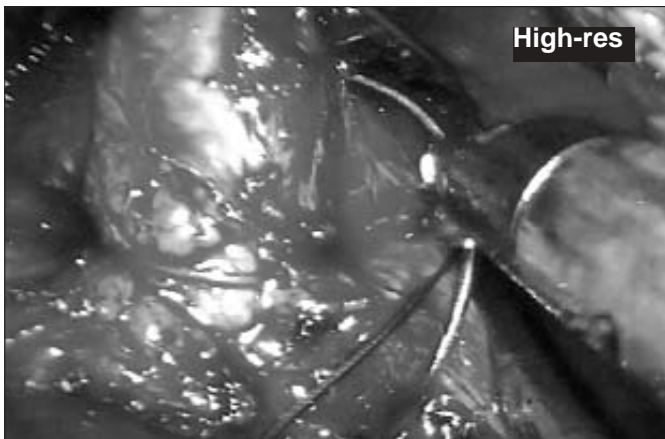
High-res

► **FIGURE 13-7.** Clearing of working space. As with conventional laparoscopy, clearing the working space allows improved visualization of surgical planes and diminished problems of clogging the suction device if there is bleeding. The fat is cleared from the endopelvic fascia and puboprostatics to the junction between the prostate and the bladder.

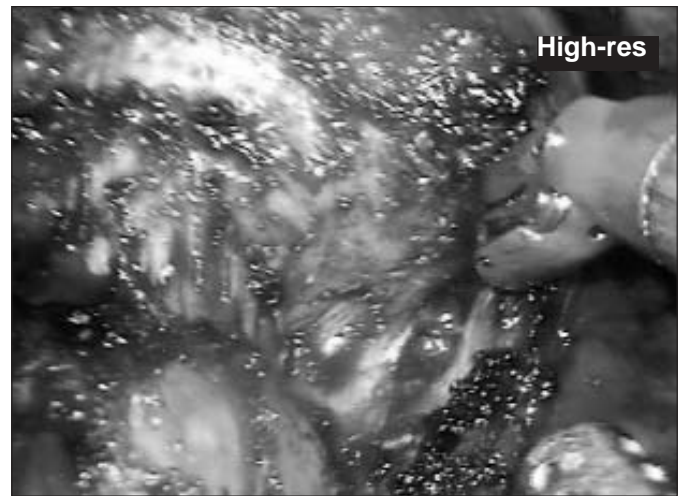


► **FIGURE 13-8.** A, Endopelvic fascia, and B, apical dissection. Sharp scissor dissection or electrocautery can start the endopelvic dissection lateral to the prostate. Work is carried proximally to the prostaticovesical junction, which is identifiable by a “V” shaped tongue of perirectal fat. As the condensations of the endopelvic move distally, they merge into the pubo-

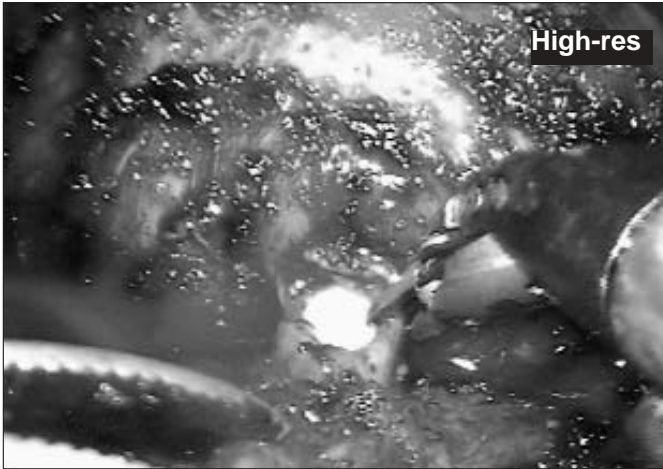
prostatic ligaments. Levator and pubourethral musculature appears to regularly insert into the visceral fascia of the prostate laterally, and forms a “sling” around the dorsal vein fascia distally. We spare as much musculature as possible by using blunt dissection primarily, and bipolar electrocautery only when necessary.



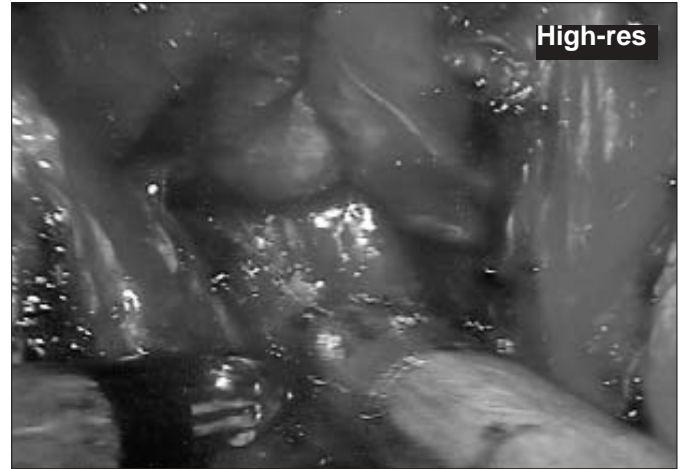
► **FIGURE 13-9.** Control of dorsal vein complex. The surgeon can decide whether to use a suture ligature or stapler at the apex. An EndoGIA stapler can nicely expose the urethra with minimal bleeding, but requires more dissection of the DVC and puboprostatics to allow placement of the device. Urethral transection theoretically is possible with the stapler. When distinguishing the urethra is difficult, gentle manipulation of the Foley catheter can help in identifying the demarcation between urethra and the dorsal venous complex. This same maneuver is useful when throwing a suture ligature to control the DVC. An advantage of using the stapler is the resulting clear visualization of the urethra. This will allow a precise urethral dissection and potentially reduce iatrogenic apical margins later in the operation [13]. Despite this, in our experience, a simple figure of eight suture using 0-Mersilene, which has a high coefficient of friction and thus resists slippage off of the DVC fascia, is all that is required to effectively control the DVC and is more cost efficient.



► **FIGURE 13-10.** Anterior bladder neck dissection. The successful dissection of the bladder neck is critical for creating the conditions for a simple urethrovesical anastomosis at the end of the procedure. The border between the prostate and bladder can be identified visually if the overlying prostatic fat is removed and is best identified at the lateral aspects. The 30 degree down lens provides a good view for this portion of the operation, and the surgeon can use it until the start of the urethral portion of the urethrovesical anastomosis. Moving the Foley catheter all the way into the bladder and then slowly pulling it back can also help identify the proper plane of dissection. An experienced assistant is invaluable for providing irrigation and counter-traction at this step. Our dissection proceeds close to the capsule of the prostate. Starting laterally on each side of prostaticovesical junction, the surgeon uses the lateral aspect of the prostate as a landmark and starts the creation of a trough towards the midline. Bleeding can occur laterally with perivesicular veins and can occur if dissection occurs into the prostate or too far into the detrusor musculature. A combination of sharp and blunt dissection will identify the bladder neck in the midline, and the proper plan is maintained by staying in the layer of periprostatic fat, present between the bladder neck and prostate laterally. The lateral approach also nicely exposes any median lobe that might be present, thereby facilitating blunt dissection of this lobe off of the posterior aspect of the bladder neck.

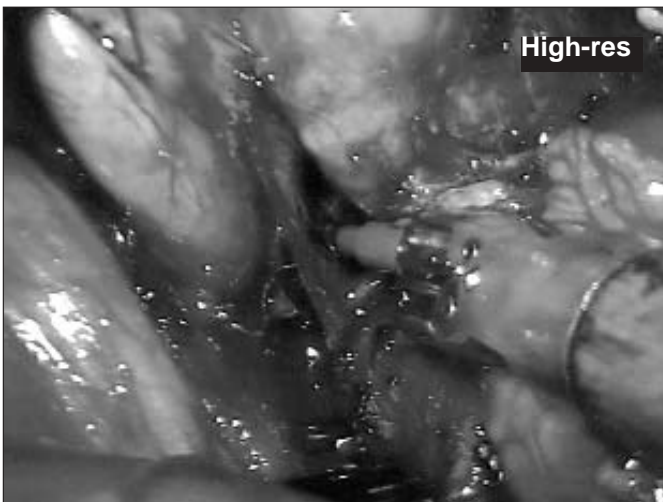


► **FIGURE 13-11.** Cut bladder neck. Cutting into the bladder will reveal the Foley catheter, which the fourth arm or the assistant can grasp to provide counter-traction for the posterior bladder neck dissection.



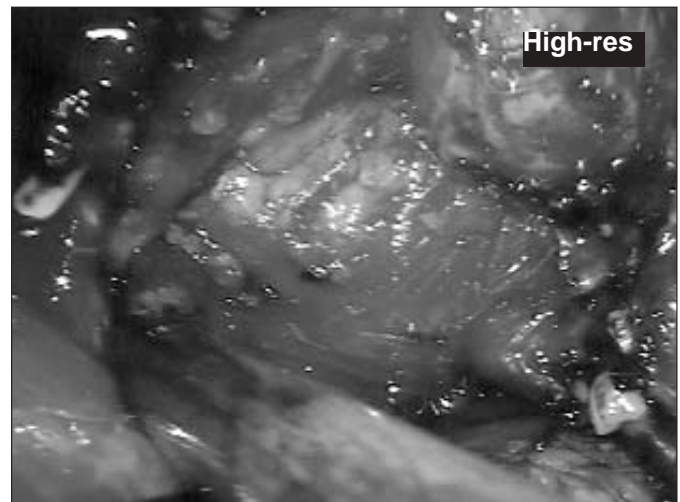
► **FIGURE 13-12.** Posterior bladder neck dissection. After the Foley catheter is elevated by the assistant, the bladder neck mucosa can be seen posteriorly following the contour of the base of the prostate into the urethra. This bladder neck is developed starting laterally with sharp and blunt dissection, sweeping the bladder neck off of the prostate. The detrusor fibers will give way to expose the anterior layer of Denonvillier's fascia. At this point, it is convenient to transect the posterior lip of mucosa forming the bladder neck. Dissection can quickly proceed to the anterior layer of Denonvillier's fascia, already established laterally. If a median lobe is present, the steps are similar except that the mucosa covering the median lobe should be transected at the neck of the median lobe and then bluntly dissected to reach Denonvillier's fascia. If the ureteral orifices are difficult to locate, the anesthesiologist can administer intravenous methylene blue.

An important point is to establish the thickness of the bladder neck wall. The thickness usually is the same circumferentially. This can help as a landmark during difficult dissections and can prevent a button-hole dissection into the posterior bladder.



► **FIGURE 13-13.** Seminal vesicles and vasa. Cutting through the Denonvillier's fascia will reveal loose connective tissue encasing the seminal vesicles and vasa. This dissection can appear very deep, especially with a large prostate. To avoid dissecting into a hole, it is helpful to work laterally, as well as to continue to bring the bladder off the prostate. This will also help maintain orientation during this task.

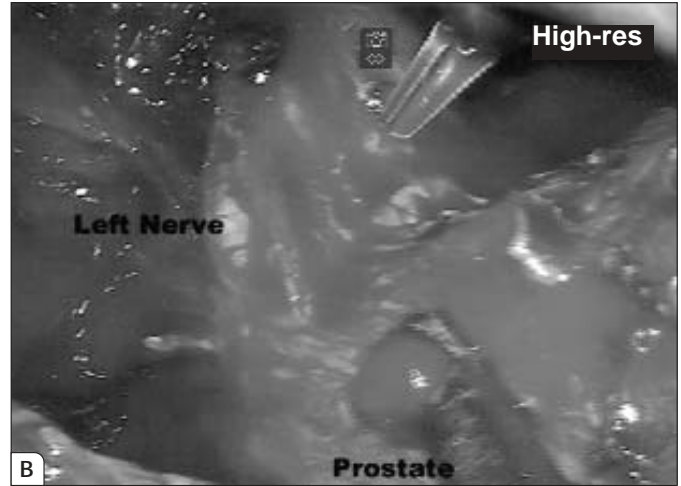
We fully remove the seminal vesicles for oncologic purposes, but are careful to use scissor and bipolar dissection or clips to control the vessels to the vasa and the seminal vesicles to minimize injury to the neurovascular bundles.




► **FIGURE 13-14.** Posterior dissection. To begin the posterior dissection, the seminal vesicles and vasa are grabbed and placed on upwards traction by the assistant. When posterior Denonvillier's fascia is transected close to the base of the prostate, the lobulated perirectal fat becomes apparent. Blunt and sharp dissection can establish the pedicles of the prostate. The plane of dissection should keep the posterior surface of the prostate apparent in order to avoid dissection too close or into the rectum. This posterior dissection can be carried all the way to the urethra if desired.




► **FIGURE 13-15. A,** Control of vascular pedicles and neurovascular bundle dissection. Anatomically, the vascular pedicles originate lateral to the seminal vesicles. Electrocautery or Weck clips are used to control the pedicles. With the increased magnification provided by the robot, the individual branches originating from the inferior vesicular artery can be coagulated precisely with bipolar cautery. As the pedicles are dropped, the





neurovascular bundles can be dissected away from the prostate. Moving in an antegrade fashion allows the bundles to be brought away from the prostate under direct vision. The bundles travel posterolaterally along the prostate and then are lateral and posterolateral to the urethra. **B** demonstrates a nerve-sparing approach, left.



► **FIGURE 13-16.** Urethral transection and entrapment of prostate. Apical positive margins can be minimized and the urethral length can be maximized if the urethral transection is done under hemostatic conditions. The dorsal venous complex can occasionally start bleeding again due to slippage of the DVC suture, and a second hemostatic stitch should be placed in this circumstance to ensure bloodless visualization during this portion of the procedure. The fourth arm of the robot is useful at this stage to provide traction on the midprostatic suture anteriorly and cephalad. Transection through the uncult portion of the DVC staple line is done with a scissor, which is used to transect the urethra as well. Skilled open surgeons will find it comfortable to complete the distal portion of the neurovascular bundle dissection at this stage, in a retrograde fashion. A specimen sack is deployed to “bag” the prostate and which is then removed through the camera port incision. For larger prostates, this incision is extended slightly to allow specimen removal, and then shortened again with a 2-0 prolene suture to allow a tight seal when the camera port is replaced in order to complete the operation.

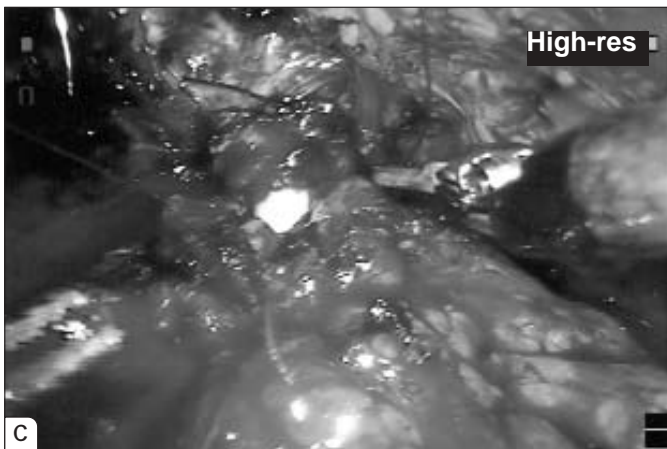


► **FIGURE 13-17.** Non-nerve sparing approach, right. In a small percentage of cases, the tumor grade and extent requires a non-nerve sparing approach unilaterally. The proximal and distal extent of the resected nerve is marked with clips.





► **FIGURE 13-18.** **A**, Proximal collagen graft, and **B**, distal collagen graft. For those patients requiring nerve grafting, the proximal and distal cut ends of the NVB are “stuffed” into the ends of a collagen tube allo-

graft (Neuragen, OriginBiomedicals, Inc., Nova Scotia, Canada) and secured with 5-0 prolene sutures.



► **FIGURE 13-19.** A, B, and C. Urethrovesical anastomosis. Perhaps the best example of the advantage of robotic surgery over conventional laparoscopy is in the performance of the anastomosis. The needle drivers can articulate at the wrist and thus allow sutures to be thrown precisely and with minimal trauma to surrounding tissues. A running, double-armed stitch popularized by Van Velthoven et al. results in a watertight anastomosis [14]. A few important points can make the anastomosis portion of the case move smoothly. Monocryl suture is useful because it can slide smoothly through tissue and thus accommodate the occasional tightening of the running anastomosis to prevent leaks. The fourth arm or the assistant can hold traction on the other arm of the stitch to prevent too much loosening of the anastomosis. If bladder neck reconstruction is needed, it can be done on the anterior or posterior portion of the bladder. If the tension required to bring the bladder down to the urethra seems to be too much, the best course of action is to place a few more throws before attempting to bring the anastomosis together. Multiple throws will dissipate the tension across the suture line and allow increased force to bring the anastomosis together.



► **FIGURE 13-20.** A, Bladder neck suspension, and B, completion of procedure. Finally, a surgeon's knot is important to prevent the closure ties

from coming apart. We typically approximate the DVC fascia to the anterior bladder neck with a final 2-0 Vicryl mattress suture to complete the procedure.

FUTURE

Almost 10% of all radical prostatectomy surgeries were performed robotically in 2004. As more surgeons surmount the learning curve, this percentage will increase. Implementation of training programs will be challenging but important to train the next generation of urologists to perform robotic surgery.

The benefits of robotic surgery include quicker recovery, diminished blood loss, and the faster recovery of continence. Data on sexual potency appear encouraging, but longer-term data from more robotic series are needed. Nerve-sparing is possible with robotics and will likely be technique dependent, just as in open surgery. Surgical positive margin rates appear to be comparable to

or better than published rates from open series. However, most importantly, the use of the DaVinci system will not magically transform surgeons with limited knowledge or skill performing prostate cancer surgery into expert surgeons, or instantly improve their outcomes. Improved outcomes come only with experience and attention to the surgical anatomy of the prostate and an understanding of the biology of prostate cancer, regardless of the method used. Conversely, the DaVinci system can allow surgeons already adept at open radical prostatectomy after years of experience and hundreds or even thousands of cases to more readily translate this hard-won skill into minimally invasive surgery for prostate cancer.

REFERENCES

1. Walsh PC: Anatomic radical prostatectomy: evolution of the surgical technique. *J Urol* 1998, 160(6 Pt 2):2418–2424.
2. Binder J, Kramer W: Robotically-assisted laparoscopic radical prostatectomy. *BJU Int* 2001, 87(4):408–410.
3. Ahlering TE, Skarecky D, Lee D: Successful transfer of open surgical skills to a laparoscopic environment using a robotic interface: initial experience with laparoscopic radical prostatectomy. *J Urol* 2003, 170:1738–1741.
4. Grossfeld GD, Chang JJ, Broering JM, *et al.*: Impact of positive surgical margins on prostate cancer recurrence and the use of secondary cancer treatment: data from the CaPSURE database. *Urology* 2000, 163:1171–1177.
5. Epstein JI, Partin AW, Sauvageot J, *et al.*: Prediction of progression following radical prostatectomy. A multivariate analysis of 721 men with long-term follow-up. *Am J Surg Path* 1996, 20:286–292.
6. Eastham JA, Kattan MW, Riedel E, *et al.*: Variations among individual surgeons in the rate of positive surgical margins in radical prostatectomy specimens. *J Urol* 2003, 170:2292–2295.
7. Hernandez DJ, Epstein JI, Trock BJ, *et al.*: Radical retropubic prostatectomy. How often do experienced surgeons have positive surgical margins when there is extraprostatic extension in the region of the neurovascular bundle? *J Urol* 2005, 173:446–449.
8. Tewari A, Srivasatava A, Menon M; Members of the VIP Team: A prospective comparison of radical retropubic and robot-assisted prostatectomy: experience in one institution. *BJU Int* 2003 92:205–210.
9. Ahlering TE, Woo D, Eichel L, *et al.*: Robot-assisted versus open radical prostatectomy: a comparison of one surgeon's outcomes. *Urology* 2004, 63:819–822.
10. Coakley FV, Eberhardt S, Kattan MW, *et al.*: Urinary continence after radical retropubic prostatectomy: relationship with membranous urethral length on preoperative endorectal magnetic resonance imaging. *J Urol* 2002, 168:1032–1035.
11. Jean J: Cost-profit analysis of daVinci robotic surgery: Is it worth it? *J Urol* 2005, 173(4 suppl):7.
12. Pick DL, Lee DI, Skarecky DW, *et al.*: Anatomic guide for port placement for daVinci robotic radical prostatectomy. *J Endourol* 2004, 18:572–575.
13. Ahlering TE, Eichel L, Edwards RA, *et al.*: Robotic radical prostatectomy: a technique to reduce pT2 positive margins. *Urology* 2004, 64:1224–1228.
14. Van Velthoven RF, Ahlering TE, Peltier A, *et al.*: Technique for laparoscopic running urethrovesical anastomosis: the single knot method. *Urology* 2003, 61:699–702.